



PATIENT

Maple Larochelle

SPECIES

Feline

BREED

DSH

SEX

Female Spayed

AGE

10 months

WEIGHT

9lbs

INTERPRETED BY

Maggie Machen Lamy,
DVM, DACVIM
(Cardiology)

IMAGING PERFORMED BY

Karen Ebersole,
DVM, DABVP

HOSPITAL NAME

Scanvet

REFERRING VET

Dr. Lane

INVOICE

32208

DATE

8/8/23

PRESENTING CLINICAL SIGNS

History: Presented with dyspnea. History of a grade 1-2/6 murmur. PE: RR 50, Heart sounds muffled. BCS 5/9.

-Radiographs: Pleural effusion and possible cardiomegaly. Pleural tap, small amount: SG 1.020, clear with some small sediment.

RADIOGRAPHIC FINDINGS *NOTE: Images submitted for supplemental cardiac information only.
Cardiomegaly. Pleural effusion.

ECHOCARDIOGRAM FINDINGS

2D, m-mode, color flow and doppler imaging is available. The left ventricular wall is moderate to severely increased in dimension with a decreased chamber size. There is a mildly hyperechoic endocardium consistent with fibrosis. The papillary muscles are mildly remodeled and hypertrophied. The endocardium also appears remodeled. The left atrium is moderately dilated in size. No obvious smoke seen. The right atrium is mildly dilated. The right ventricle appears mildly affected as well. The mitral valve is normal in structure and mobility. Trace MR. Trace TR. Blood flow through both the LVOT and RVOT is normal in velocity. Scant pericardial effusion seen. Scant pleural effusion. No obvious cardiac tumors.

CARDIAC CHART

FELINE CARDIAC PARAMETERS	BODY WEIGHT (kg)	HR (BPM)	IVSd (cm) <small>(Moise, Pipers)</small>	LVIDd (cm) <small>(Moise, Pipers)</small>	LWVd (cm) <small>(Moise, Pipers)</small>	FS (%)	EF (%)
NORMAL PARAMETER	-----	150-240	0.35-0.55	<2 (mean 1.5)	3.5-0.55	35-67	80-100
PATIENT		190	0.77	1.2	0.77	65	95
FELINE CARDIAC PARAMETERS	LA/AO <small>(Boon)</small>	LA/AO HEART BASE (Swe) <small>(Abbott)</small>	LA 2D short axis Base view (cm) <small>(Abbott)</small>	LVOT VEL <small>(m/s)</small>	RVOT VEL <small>(m/s)</small>	E max <small>(m/s)</small>	
NORMAL	<1.5	<1.3	<1.2	<1.6	<1.3	<0.9	
PATIENT	1.8	1.9	1.5	1.0	0.6	NM	
*Note: All measurements based upon multi-modal images and methods. An average value is reported. Adapted from June Boon, Veterinary Echocardiography, 1998 Abbott J & MacLean H JVIM 2006;20: 111-119, Moise et al. Am J Vet Res 47:1476, 1986. Pipers et al. Am J Vet Res 40:882, 1979.							

INTERPRETATION OF THE FINDINGS & FURTHER RECOMMENDATIONS

Hypertrophic cardiomyopathy (HCM) is a rule out diagnosis for LV hypertrophy once a patient is confirmed euthyroid and normotensive. Both should be considered in this case, although given the age of the patient primary disease is suspected. The left atrium is moderately enlarged, indicating risk for spontaneous CHF and/or blood clot events going forward. No additional issues are identified.

Given these findings, the diagnosis of CHF is likely and full cardiac support should be instituted as below. It is worth mentioning that moderate LA dilation is somewhat surprising to develop organic CHF, and contributing factors should be considered (any history of fluid or steroid



PATIENT

Maple Larochelle

therapy, etc.). Regardless, continued treatment is recommended as below. Steroid or fluid therapy should certainly be avoided in this case.

SPECIES

Feline

Depending on patient's stability continued hospitalization should always be considered. The mean survival time for cats with CHF is 8-12 months; however, most cats are able to maintain a good quality of life on medications. Patient will always be at high risk for recurrent episodes of CHF and development of blood clots in the future. Monitoring of sleeping breathing rates at home is recommended as the best way to screen for recurrent CHF at home.

BREED

DSH

PLAN

Consider injectable Lasix dose/hospitalization until stable. Baseline ECG and BP recommended. Once stable, discharge on the following: Administer diuretic 1-2mg/kg PO q12h. Administer Pimobendan 1.25mg PO q12h. If able, administer blood thinner Clopidogrel (Plavix) 75mg tablets; give ¼ tab orally once daily (NOTE: this medication is very bitter on the cut edges). Monitor renal values and BP in 1-2 weeks then every 3-4 months lifelong. If doing well and BP >130mmHg, institute ACEI 0.5mg/kg PO q12h. If difficult to medicate or hypotensive, do not utilize.

SEX

Female Spayed

AGE

10 months

A recheck echocardiogram is recommended in 6 months to assess progression.

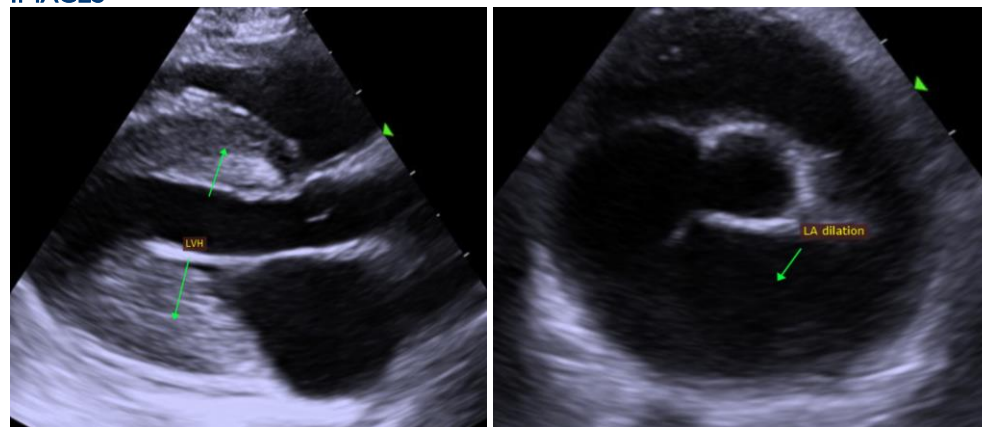
WEIGHT

9lbs

IMAGES

INTERPRETED BY

Maggie Machen Lamy,
DVM, DACVIM
(Cardiology)



IMAGING PERFORMED BY

Karen Ebersole,
DVM, DABVP

HOSPITAL NAME

Scanvet

The information and recommendations provided are based on the images presented by the referring veterinarian. No evaluation can be communicated regarding pathology that was not visible in the image/video clips provided.

REFERRING VET

Dr. Lane

Thank you for this referral. This report was generated using transcription software, and minor dictation errors may be present. If the clinical or image interpretation does not parallel your findings or if I can be of any further assistance, please contact me.

INVOICE

32208

Maggie Machen Lamy, DVM
Diplomate of the American College of Veterinary Internal Medicine (Cardiology)
info@sonopath.com

DATE

8/8/23